

# Spontaneous acute spinal subdural hematoma-the importance of fast and accurate diagnosis

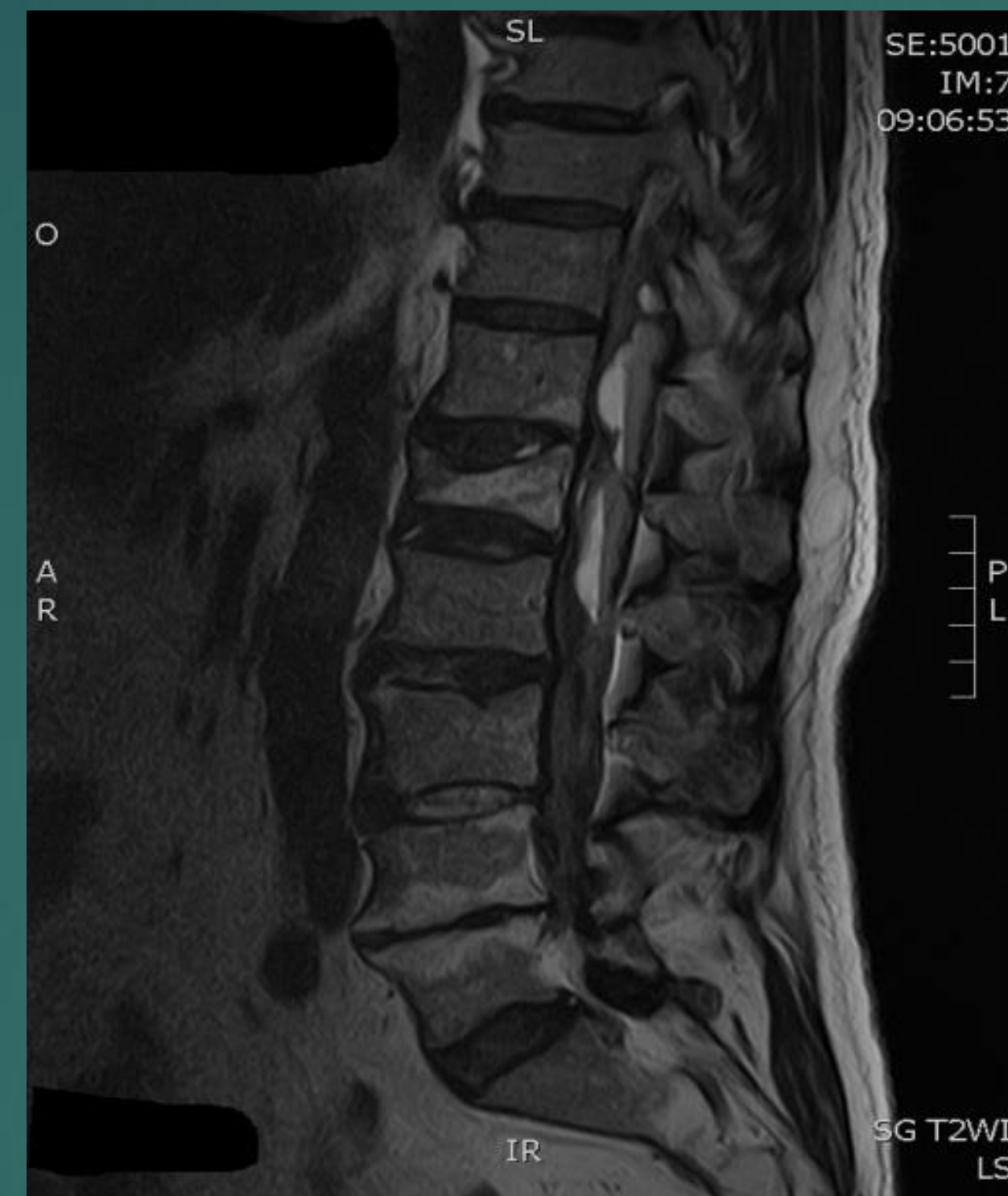Svetlana Kocić<sup>1</sup>, Nenad Janeski<sup>1</sup>, Aleksic Vuk<sup>2</sup>

<sup>1</sup> Department of radiology, Clinical hospital center Zemun, Belgrade, Serbia

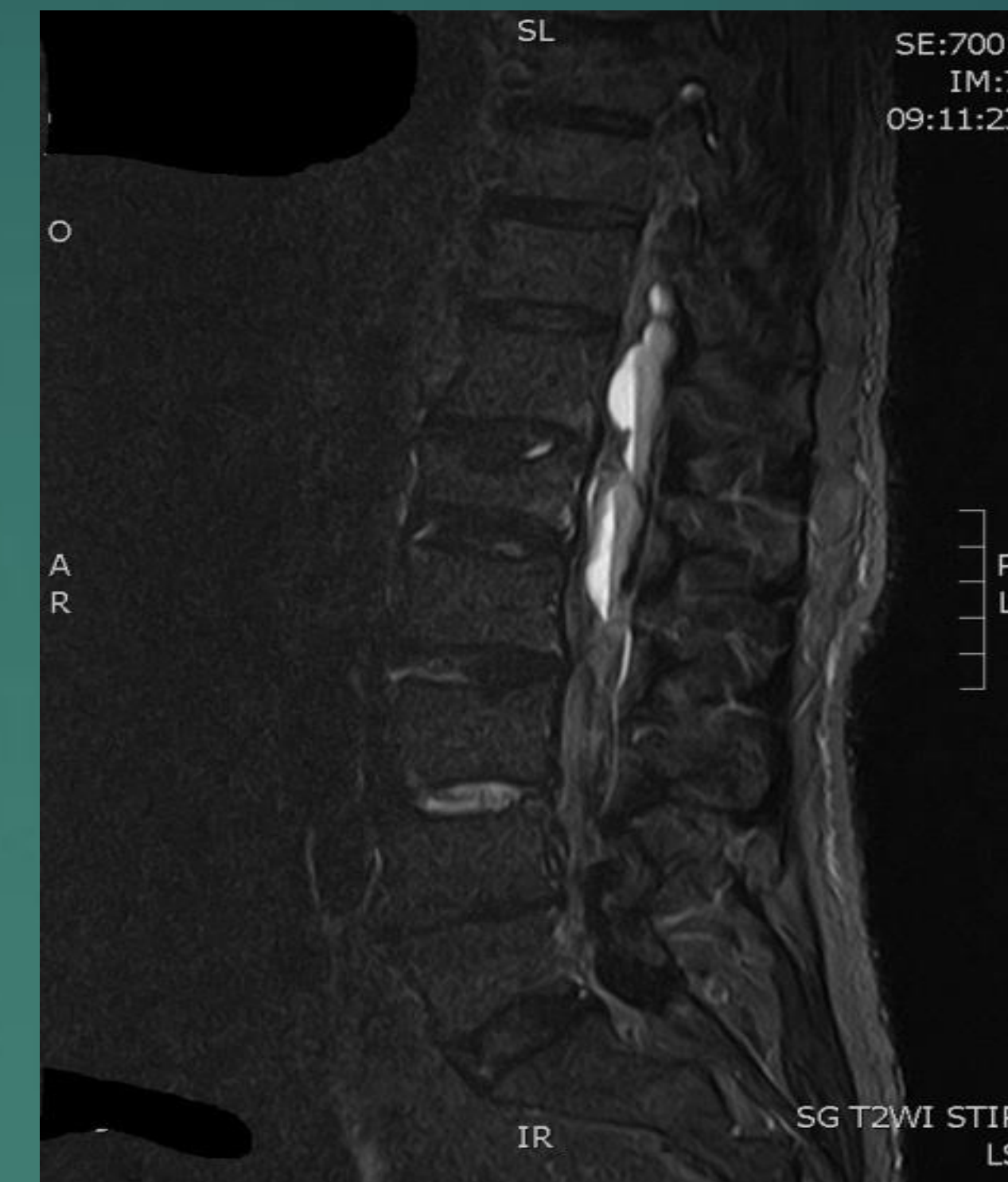<sup>2</sup> Department of neurosurgery, Clinical hospital center Zemun, Belgrade, Serbia

Spontaneous spinal subdural hematoma (SSDH) as a result of anticoagulant therapy is exceedingly uncommon condition with incidence lower than 1%.

Symptoms can vary according to the level of the bleed causing back pain with a radicular component, weakness and complete paraplegia.



a) Sagittal T2W image showing Th12-L2 hyperintense subdural hematoma



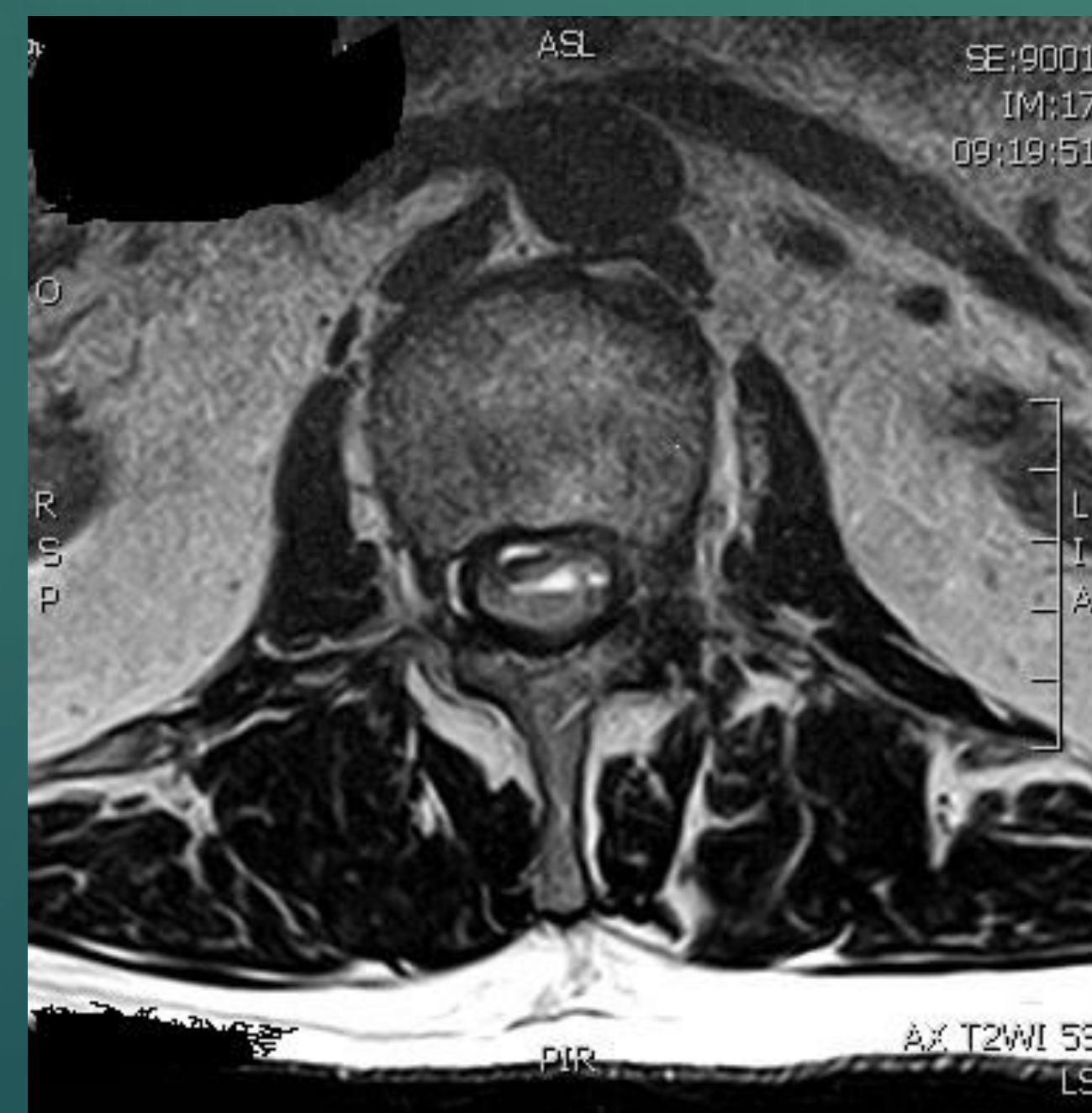b) Sagittal STIR image showing hyperintense subdural hematoma

The differential diagnosis includes abscess, lipomatosis, significant discal hernia and tumors..

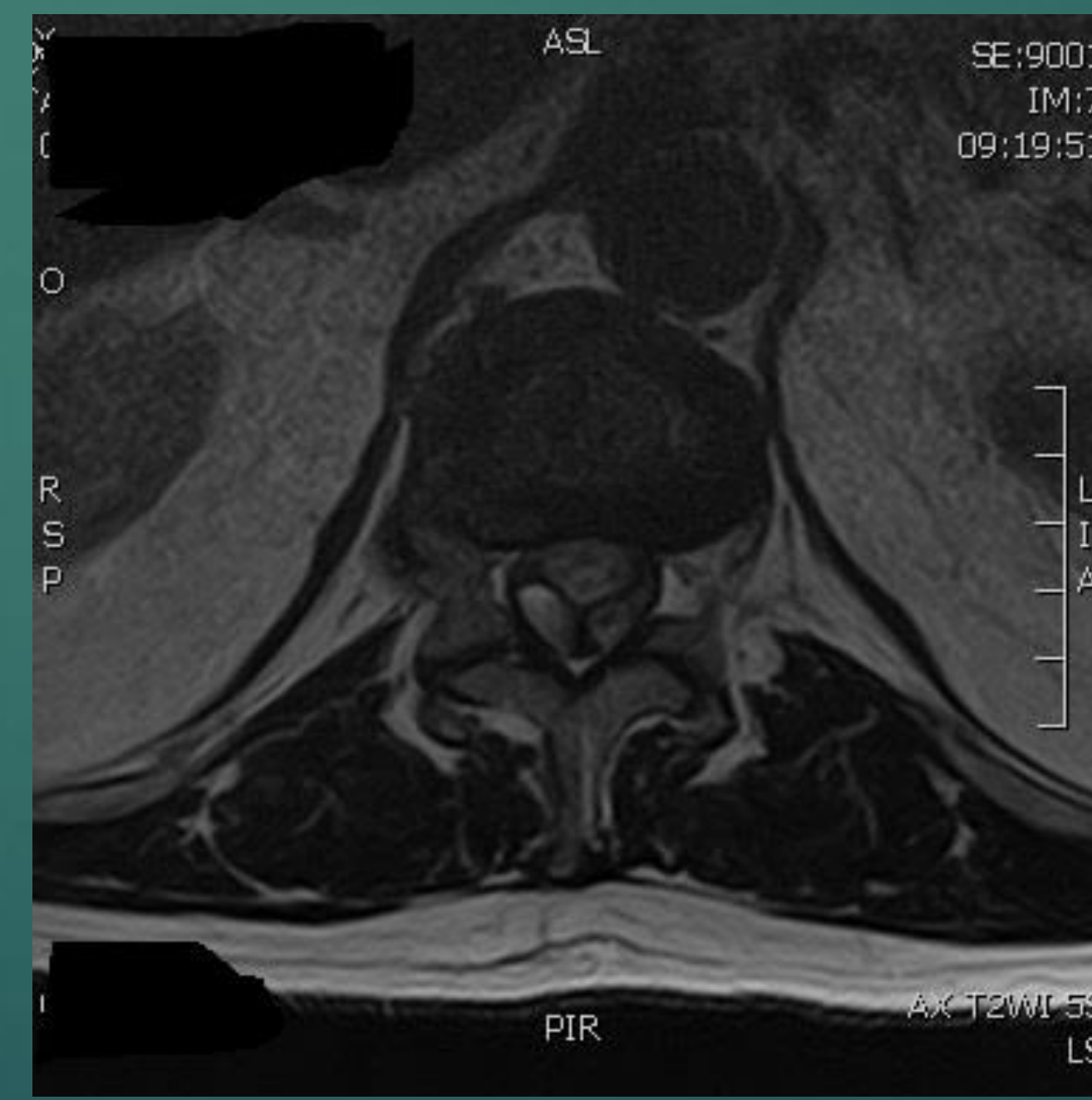
There are no definite guidelines for management SSDH.

The location and symptoms are the most important factors for treatment decision.

Treatment involves conservative management in cases with preserved neurology or laminectomy and drainage in cases with serious neurological deficit



c) Axial T2W showing the "Y" shaped sign of the SDH at the level of L1



d) Axial T2W showing SDH at the level Th12 causing absolute spinal stenosis

A 75 years-old man with progressive bilateral lower limb radiculopathy, paresthesias and lower back pain progressing to paraplegia and urine incontinency .

There was no history of trauma. The patient had inserted aortic valve prosthesis 5 years ago and was on anticoagulant therapy .

Prompt recognition of the presence of spinal subdural hematoma is crucial

MR is the investigation of choice for diagnosis as well as for planning the surgery.

The most important factor to distinguish SDH from other spinal lesion is identification of blood products on MR.

MR gives better visualization of the longitudinal extent and size of the hematoma.

Subdural hematoma can be divided into hyperacute, acute and chronic.